

Image Registration Assists Novice Operators in Ultrasound Assessment of Abdominal Trauma*

Kirby G. VOSBURGH,^{1,2,3} Jeffrey STOLL,² Vicki NOBLE,³ Kilian POHL,⁴ Raul SAN JOSÉ ESTEPAR,² Barnabas TAKACS⁵

Abstract: Transcutaneous ultrasound imaging may be used to detect abdominal hemorrhage in the field setting. The Focused Assessment with Sonography for Trauma (FAST) examination was developed to characterize blunt abdominal trauma and has been shown to be effective for assessing penetrating trauma as well. However, it is unlikely that a minimally trained operator could perform a diagnostic examination. In our system, the operator is supported by real-time 3D volume displays. The operator will be directed through the examination by prompts from a computer system or outside expert, potentially with knowledge of the anatomy of the injured patient. The key elements of the tele-operated FAST exam capability have been demonstrated; the exam is performed with real-time guidance from anatomic images registered to the body. It appears likely that Image Registration will assist hemorrhage detection at the point of injury or in the initial evaluation by a trauma response team.

Keywords: Ultrasound, FAST examination, trauma, image guidance, image registration.

Introduction

To detect abdominal hemorrhage in the field setting, whether from penetrating or concussive insults, the diagnostic instrument of choice for the near future will be transcutaneous ultrasound imaging. This contrasts with the situation in major medical center emergency services, where CT is the easiest and most definitive choice for detecting pooled blood. Several high quality, low cost, portable (battery powered or low power) ultrasound instruments are now commercially available and suitable for military use. The Focused Assessment with Sonography for Trauma (FAST) examination [1] was originally developed to characterize blunt abdominal trauma, but has been shown to be effective for assessing penetrating trauma as well. [2] FAST

* Supported by the US Army under Contract #W81XWH04C0031 (WaveBand Corporation) and by CIMIT under Cooperative Agreement DAMD 17-2-2-0006, both through the Telemedicine and Advanced Technology Research Center (TATRC). Technology support was provided by Ascension Technologies, SonoSite, and B-K Medical.

¹ Center for Integration of Medicine and Innovative Technology (CIMIT), Boston, MA

² Brigham and Women's Hospital, Boston, MA

³ Massachusetts General Hospital, Boston, MA

⁴ Isomics, Inc., Cambridge, MA

⁵ Current Affiliation: Digital Elite Inc., Los Angeles, CA / MTA SZTAKI Budapest, Hungary

examinations have shown a sensitivity near 85% and a specificity of better than 95%. The primary indicator for a positive reading is the observation of a volume of intra-peritoneal blood in regions around the liver, spleen or the pelvic organs. The standard treatment after a positive FAST examination is a prompt exploratory laparotomy to identify and treat the injury. Use of FAST near the front lines can thus direct casualty triage. Ultrasound imaging requires a level of care and sophistication that makes it unlikely that a minimally trained, unsupported operator could perform a diagnostic examination under battlefield conditions. For this reason we have developed the technique of Image Registered FAST (IRFAST) examinations, in which the operator is provided with additional feedback and support through a visual display system to assist in the examination.

Tools and Methods

In our IRFAST system, the operator is supported by real-time 3D volume displays and potentially by telecommunications linkages. The system is based on technology developed and demonstrated for the augmentation of laparoscopic and endoscopic interventions. [3-6] The operator is directed through the examination by prompts from a computer system or outside expert, potentially with knowledge of the anatomy of the injured patient. The project has had three primary tasks:

1. Development of patient-specific segmented CT-based models to enable accurate navigation and probe positioning. The automatic segmentation of anatomical compartments from 3D Computed tomography (CT)-torso scans is very difficult as the compartments may have weakly visible boundaries, similar intensity patterns to compartments in close vicinity, large variations of their spatial location within a population, and scans might be corrupted by image artifacts such as noise. One way of addressing these issues is to develop segmentation algorithms that couple image data with prior information about the anatomical compartments. Over the last decade the medical imaging community has developed a variety of methods targeted towards segmentation of specific compartments in CT scans such as lungs. These methods frequently model specific characteristics of the anatomical compartments such as the tubular like structure of vessels and ribs. In this project, we developed a different approach that does not focus on a specific structure, but segments the CT scan in most of the major anatomical compartments in the torso. The approach is guided by prior information represented within a tree structure. [7] The tree mirrors the hierarchy of anatomical structures and the sub-trees correspond to limited segmentation problems. The solution to each problem is estimated via a segmentation approach that combines intensity thresholding, template matching, and previous segmentation results.

We relate the segmentation of CT images to a tree representing the hierarchical relationship between anatomical compartments. The nodes of our tree represent anatomical compartments and the edges of the tree capture the hierarchy between different regions of interest. For example, the lung region is a parent node of right and left lung, and the bronchial tree. The key idea is that prior information can be stored at each node and the segmentation task is simplified by subdividing it into less complex segmentation problems. For example, the automatic segmentation of lungs simply based on intensities of the CT scan is difficult as they are similar to the ones of the background. However, if the approach first identifies the torso, then the automatic segmentation of the lungs is simplified. The process starts at the root of the tree,

segmenting the image into the children of the root. A recursive process follows where each child becomes a root and the region of interest (ROI) associated with the new root is segmented into its children. The root of the tree represents the entire region to be segmented, the leaves represent the final compartments of interests, and the inner nodes are intermediate coarser anatomical ROIs. A node X is a child of another node Y if the structure associated with X is a substructure of the structure associated with Y.

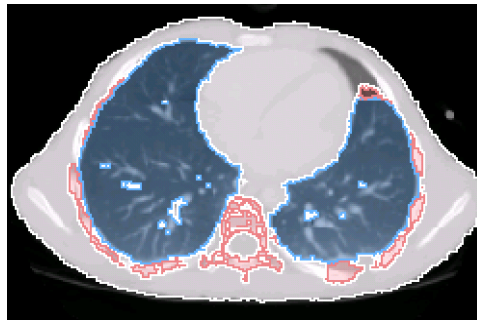


Figure 1: Label map of the lungs based on registration

The segmentation task associated with each node is solved in two steps. First a template is registered to CT scan using the previous segmentation results. In the second step, the results of the registration are coupled with an analysis of the intensity histogram to segment the node into its children.

Figure 1 shows the template of the lung mapped onto the CT scan of the subject. Parts of the lung in the scan (dark voxels inside the torso) are missed by the template. We note, however, that the registration is improved when aligning label maps instead of CT images.

2. A tracked ultrasound probe is registered with the patient and the CT anatomy to create an Image Registered FAST (IRFAST) capability.(Fig 2). This system is the latest Image Registered system to be developed by the CIMIT Image Guidance Laboratory; see www.ciglab.org. In prior work for CT registration we used bead markers on the skin or the tips of the ribs of a pig. Either of these methods gives usable registration of about 0.5 cm accuracy in x,y,z combined, but neither are practical for the IRFAST technique for human subjects. Thus a key task was to explore new, non-invasive localization approaches.

3. Evaluation of the IRFAST system with human operators in comparative porcine model hemorrhage studies.

Results

The key elements of the tele-operated FAST exam capability have been demonstrated. The development of rapid, nearly unguided anatomical segmentations of volumetric CT images, led by Dr. Pohl, was successful. We developed a segmentation approach that segments CT scans into several anatomical compartments within the torso by using prior information encoded within a tree structure. The tree structure guides the algorithm separating the segment problem in several easier to solve sub tasks. Figure 3 shows the automatic segmentation of a CT scan into the body (pink), bone structures (gray), lungs (blue), heart (red), main artery (yellow), and kidneys (green) . The CT scan has the dimension 512x512x404 voxels, We note that our approach robustly identifies the structures of interests in this CT scan. While we achieved promising results on a small set of CT scans, we yet have to measure the accuracy of the approach on a larger set of CT scans.

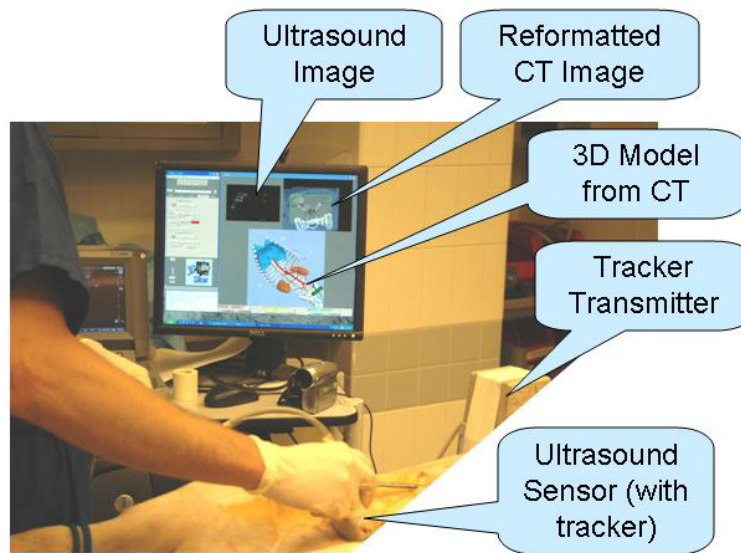


Figure 2: IRFAST system in use

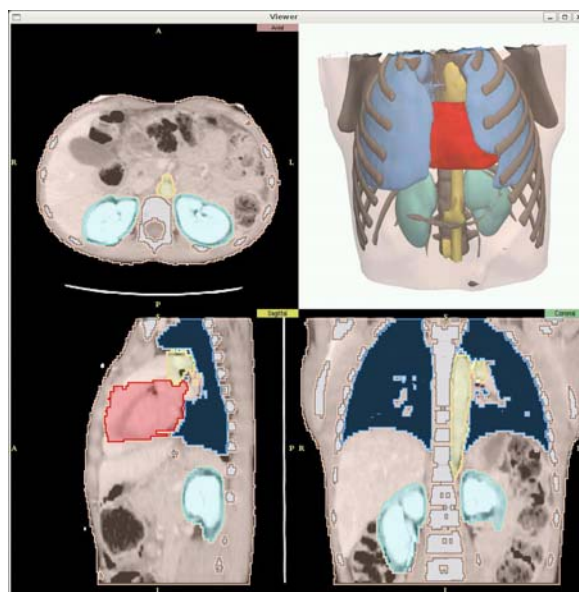

Figure 3. Automatic segmented CT volumes

For Ultrasound experiments, a SonoSite Titan system equipped with a C60/5-2 Curved Array Transducer was used for all system evaluations. The exam is performed with real-time guidance from anatomic images registered to the body. To achieve real time registration between the archival CT data and the real time ultrasound, we mapped out the rib arch and spline fitted to determine transverse and vertical location, and identifying the xyphoid and clavicular notch to determine the main body axis. These do not always give reproducible results due to uncertainties in positioning the probe on the skin, so applied fiducial markers were used when necessary for some of the experiments. To evaluate the operator interface, pre-existing applied fiducials were used. Experienced FAST operators found some of the IRFAST features of minimal use. Their principal concern in this unstructured test was the differences between pig and human anatomy, particularly in the position of the kidneys relative to the rib arch. However, the porcine model system did provide an image of free blood in the abdomen comparable to that seen in humans.

With human subjects, our approach to registering the ultrasound transducer to the CT model is based on the use of natural anatomic landmarks. The shape of the ribcage permits relatively easy localization of one point on the longitudinal axis, the umbilicus provides another such point. Transverse and vertical references may be obtained with a simple fixture on the rib cage, although compensation is necessary for the respiratory cycle.

The full system was successfully implemented and evaluated by a small number of operators using the porcine model. Initial results show the anticipated benefits (Table 1.) in guiding inexperienced operators, where the order of using the IR-enhanced system shows significant changes in scan times. The mean time for scanning improves significantly for identification of the FAST examination landmarks when the IRFAST Display is used (subject 2). If the order of use of IRFAST is reverse (subject 3.) the “training effect” is not as strong.

Table I. Comparative performance in the use of IRFAST

	Scan #1 time	Scan #2 time	Mean diff. time
IR display second (subject 2)	122 sec	50 sec	62%
IR display first (subject 3)	32 sec	18 sec	36%

Initial experiments were also conducted to design an optimized display to guide the FAST examination by an inexperienced operator. Fig 4. shows such a view of the body in segmented form, with the desired location of the scan shown in a highlighted color. In future work, the utility of such systems for proctoring the examination will be evaluated.

Discussion

It appears likely that Image Registration will assist hemorrhage detection at the point of injury or in the initial evaluation by a trauma response team. The analysis or our experiments as presented here is complicated by differences between human and porcine anatomy. A challenge facing our overall approach is the likelihood that, in the

near term, there will be no prior CT examination available. We may assume, however, that the patient's general anatomic properties are easily available. With such parameters as height, weight, body type, and gender, we anticipate that we will be able to provide a surrogate CT structure sufficient for the task.

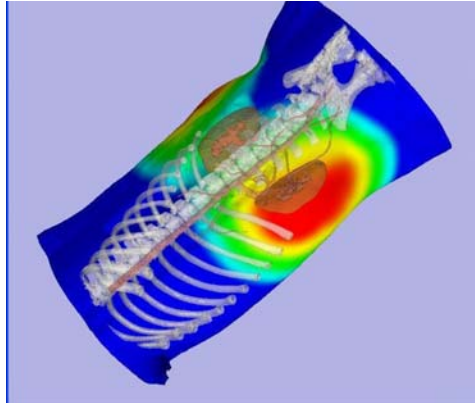


Figure 4. Highlighted anatomic model showing optimized scan locations for guiding inexperienced operators.

References

- [1] Noble, V, B. Nelson, N. Sutingco, Manual of Emergency and Critical Care Ultrasound, Cambridge U. Press, 2007, ISBN:0521688698
- [2] Udobi, K, A. Rodriguez, W. Chiu, T.M. Scalea, Role of Ultrasonography in Penetrating Abdominal Trauma: A Prospective Clinical Study. *J. Trauma* 2001;50:475-9
- [3] Vosburgh, KG, N. Stylopoulos, R. San Jose Estepar, RE Ellis, E. Samset, CC Thompson. EUS and CT Improve Efficiency and Structure Identification over Conventional EUS, *Gastrointestinal Endoscopy*, 2007;65:866-70.
- [4] Vosburgh, KG, R San Jose Estepar, Natural Orifice Transluminal Endoscopic Surgery (NOTES): An Opportunity for Augmented Reality Guidance. *Studies in Health Tech. & Inform.* 2007:125;485-90
- [5] San Jose Estepar, R, N. Stylopoulos, RE Ellis, E. Samset, C-F Westin, CC Thompson, KG Vosburgh Towards Scarless Surgery: An Endoscopic Ultrasound Navigation System for Transgastric Access Procedures. *MICCAI 2006;LNCS 4190, I; 445-453* (Springer).
- [6] Ellsmere, J, J. Stoll, W Wells III, R. Kikinis, KG Vosburgh, R. Kane, D. Brooks, D. Rattner, A New Visualization Technique for Laparoscopic Ultrasound. *Surgery* 2004;136:84-92
- [7] K.M. Pohl, S. Bouix, M. Nakamura, T. Rohlfing, R.W. McCarley, R. Kikinis, W.E.L. Grimson, M.E. Shenton, and W.M. Wells. A hierarchical algorithm for MR brain image parcellation. *IEEE Transactions on Medical Imaging*, 2007. In Press